SCIENTIFIC ARTICLE

Overcoming the Axillary Nerve Blind Spot Through the Deltopectoral and Axillary Approaches: A Cadaveric Study

Alfonso Pérez, MD,*† Bilal Mahmood, MD,‡ Rishabh Jethanandani, MD,§ Steve K. Lee, MD,||¶# Scott W. Wolfe, MD||¶#

Purpose The aim of this study was to evaluate the feasibility of exploring the axillary nerve (AN) at the 6 o'clock position (blind spot) using the deltopectoral approach, with the interval lateral to the conjoint tendon (CJT) or combined with the axillary approach.

Methods Four ANs were dissected combining the deltopectoral approach—medial to the CJ (A), the deltopectoral approach—lateral to the CJT (B) and the axillary approach (C) in 3 sequences: A-B-C, B-A-C, and C-B-A. After the first approach was completed, the proximal and distal margins were marked. Additional exposure with the second and third approaches and the 6 o'clock position were also marked. Then, the AN was excised and the amount of exposed nerve with the 3 approaches was measured.

Results The deltopectoral approach—medial to the conjoint tendon did not allow exposure of the AN at the 6 o'clock position. Six o'clock position exposure was accomplished using the lateral interval of the deltopectoral and the axillary approaches. A deltopectoral approach lateral to the CJT allowed exploration of the AN at the blind spot, but not the terminal branches. The axillary approach was able to expose the AN at the 6 o'clock position, the terminal branches, but not the nerve-muscle junction. Combining the 3 approaches exposed 81% to 94% of the total length of the AN.

Conclusions The deltopectoral approach allowed visualization of the AN at the 6 o'clock position when explored lateral to the CJT. The axillary approach allowed visualization of the terminal branches of the AN and the 6 o'clock position of the glenoid.

Clinical relevance The deltopectoral approach lateral to the conjoint tendon allows the surgeon to assess continuity of the AN at the 6-o'clock position and to perform a neurolysis. If nerve repair, nerve grafting, or nerve transfer is attempted, a combination of the 3 approaches could be used. *(J Hand Surg Am. 2020;45(7):659.e1-e7. Copyright © 2020 by the American Society for Surgery of the Hand. All rights reserved.)*

Key words Axillary nerve, brachial plexus, iatrogenic injuries, shoulder, surgical exposures.



THE AXILLARY NERVE (AN) IS THE most frequently injured peripheral nerve in the shoulder. Causes of injury can range from direct trauma, shoulder dislocation, tumors, or iatrogenic injury from shoulder arthroplasty, proximal humerus osteosynthesis, capsuloplasty, or other procedures.[1]

*From the *Department of Trauma, Hand and Upper Extremity Service, Hospital del Trabajador; the †School of Medicine, Universidad Andrés Bello, Santiago, Chile; the ‡University of Rochester Medical Center, Rochester, NY; the §Charles E. Schmidt College of Medicine, Florida Atlantic University, Boca Raton, FL; the ||Department of Biomechanics; the ¶Department of Orthopedic Surgery, Hand and Upper Extremity Service, Hospital for Special Surgery; the #Weill Cornell Medical College, New York, NY*

Received for publication May 18, 2019; accepted in revised form November 26, 2019.

No benefits in any form have been received or will be received related directly or indirectly to the subject of this article.

Investigation performed at the Department of Orthopedic Surgery, Hospital for Special Surgery, New York, NY.

Corresponding author: Scott W. Wolfe, MD, Department of Biomechanics, Department of Orthopedic Surgery, Hand and Upper Extremity Service, Hospital for Special Surgery, 523 East 72nd St., 4th Floor, New York, NY 10021; e-mail: wolfes@hss.edu.

0363-5023/20/4507-0017$36.00/0
https://doi.org/10.1016/j.jhsa.2019.11.013

The risk of iatrogenic injury is particularly increased in arthroscopic procedures repairing humeral avulsion of the glenohumeral ligament or in glenohumeral capsuloplasty when sutures and/or anchors are placed in the anteroinferior or inferior margin of the glenoid (the 6 o'clock position during shoulder arthroscopy).[2] The nerve runs 10 to 18 mm distal to the inferior glenohumeral capsule, where it is at risk of injury or compression by sutures or anchors.[3–5]

If there is no physiological recovery of a suspected AN injury after 3 to 6 months of observation, exploration of the AN is indicated. Surgical exploration of the AN is challenging because of its critical proximity to the brachial plexus, the axillary artery, and the posterior circumflex humeral vessels. In addition, the oblique course of the nerve into the quadrangular space and the surrounding muscular structures (subscapularis, teres minor, teres major, latissimus dorsi, and the long head of triceps muscles) make exposure of the nerve difficult.

The most frequently used approaches for exploration of the AN are the deltopectoral approach,[6,7] the axillary approach,[8] and the posterior approach[9] (Fig. 1). Owing to anatomical restrictions, it is not possible to explore the full length of the nerve via a single approach. Selection of the surgical approach and positioning will depend on the cause of and the suspected location of the nerve injury. Traditionally, the deltopectoral approach is used to explore the origin of the nerve at the posterior cord, but it is limited in its exposure of the nerve's axillary course.[10,11] The axillary and posterior approaches allow exploration of the nerve at the quadrangular space and the terminal branches of the axillary nerve.[8,11]

Some authors advocate that, even when combining the deltopectoral and posterior approaches, a segment of the AN (at the 5 o'clock and 7 o'clock positions of the right and left glenohumeral joints, respectively) may not be adequately exposed and additional measures to extend the approach are required.[10] To address this, the same group of investigators have described a blind spot that requires detachment of the conjoint tendon (CJT) from the coracoid (anterior approach), cutting a portion of the latissimus dorsi (axillary approach), or detaching the long head of triceps (posterior approach) in order to fully expose the AN.[11] However, these maneuvers may be associated with morbidity.

The purpose of the study was to determine whether there is a true blind spot of the AN. We questioned whether a deltopectoral approach with an accessory window lateral to the CJT would allow visualization of the 6 o'clock blind spot position. We further sought to confirm that the axillary approach enables increased operative capabilities for repair of the AN and effectively eliminates the blind spot.

We hypothesized that the deltopectoral approach with an accessory window lateral to the CJT increases the length of exposure of the AN, including the blind spot, when compared with the traditional medial deltopectoral approach. Second, we hypothesized that a combination of the 3 windows—deltopectoral medial to the CJT, deltopectoral lateral to the CJT, and the axillary approach—is sufficient to expose and repair the AN.

MATERIALS AND METHODS

Four cadaveric plexuses (Table 1), with no previous trauma, surgery, or obvious abnormality, were dissected using 3 sequential approaches to explore the AN.

A. (1) Deltopectoral approach medial to the CJT—(2) deltopectoral approach lateral to the CJT—(3) axillary approach.
B. (1) Deltopectoral approach lateral to the CJT—(2) deltopectoral approach medial to the CJT—(3) axillary approach.
C. (1) Axillary approach—(2) deltopectoral approach lateral to the CJT—(3) deltopectoral approach medial to the CJT.

Sequence C was performed in 2 specimens. Specimens were positioned supine with the shoulder in 45° of abduction and 45° of external rotation for deltopectoral approaches. For the axillary approach, the shoulder was positioned in 90° abduction and maximal external rotation.

Deltopectoral approach medial to the CJT

A 7-cm skin incision, centered on the deltopectoral interval, was performed as described by Henry.[6,11] The interval between the pectoralis minor and the coracobrachialis was used. The posterior cord, AN, and radial nerves were identified after the lateral cord, axillary artery, and medial cord were dissected and retracted medially. Dissection of the AN was carried out as distally as possible without ligating branches of the axillary artery. Surgical titanium clips (Surgiclip; Covidien, Minneapolis, MN) were used to mark the most proximally and distally visualized parts of the AN (Fig. 2).

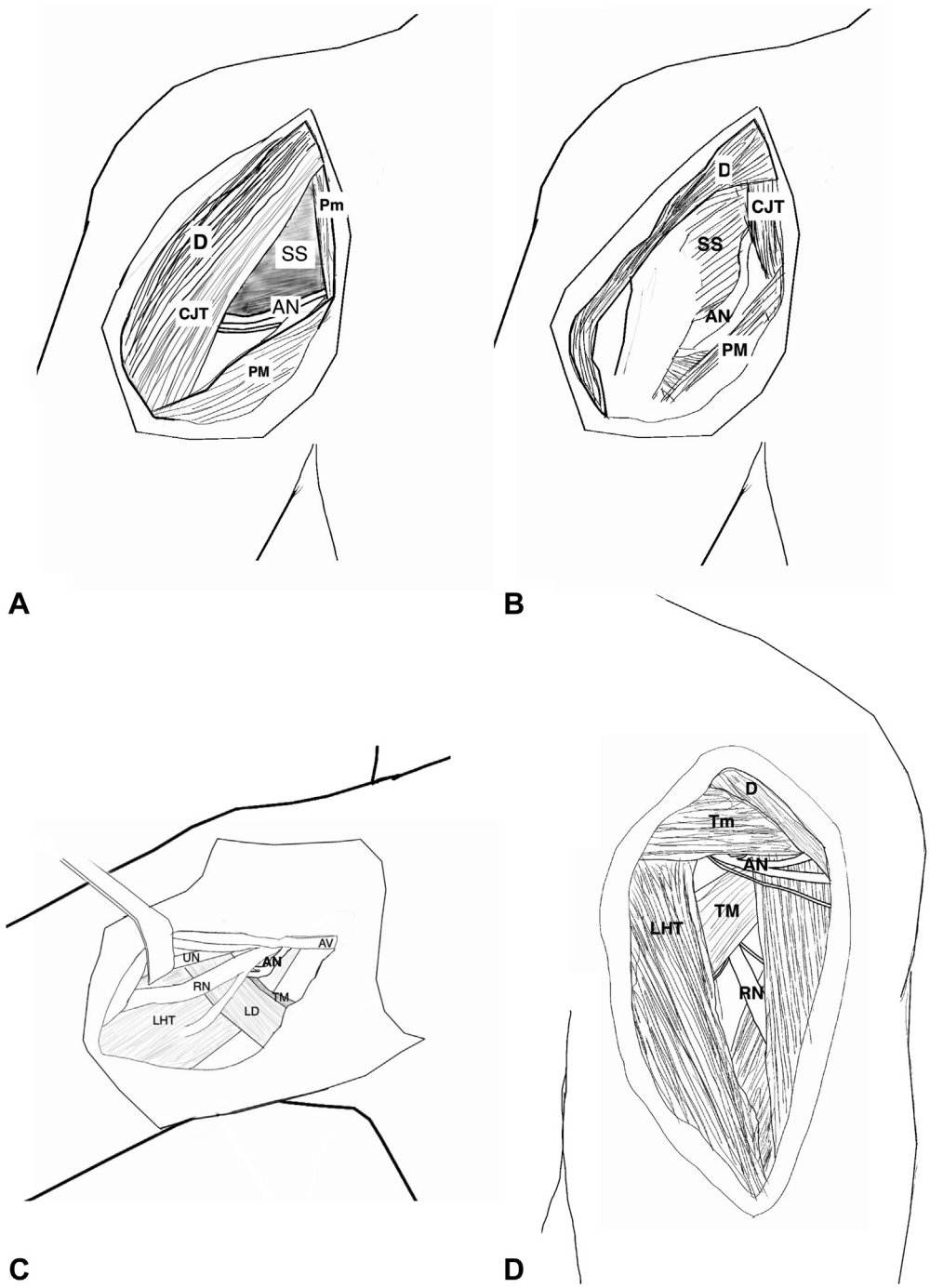

FIGURE 1: Surgical approaches used to explore the AN. **A** Deltopectoral approach medial to the CJT (right shoulder, anterior view). **B** Deltopectoral approach lateral to the CJT (right shoulder, anterior view). **C** Axillary approach (anterior view of right axilla, shoulder 90° abduction and external rotation). **D** Posterior approach (right shoulder, posterior view). AV, axillary vein; D, deltoid; LD, latissimus dorsi; LHT, long head of triceps; PM, pectoralis major; Pm, pectoralis minor; RN, radial nerve; SS, subscapularis; TM, teres major; Tm, teres minor; UN, ulnar nerve.

Deltopectoral approach lateral to the CJT

The same skin incision was used as the previous approach. The approach for common open procedures to the glenohumeral joint (eg, Bankart repairs, glenohumeral arthroplasty) was then performed, leaving the plexus medial to the CJT and exposing the subscapularis muscle and tendon.[6,7] The anterior margin of the deltoid was retracted laterally. The CJT was retracted medially, avoiding excessive tension that could damage the musculocutaneous nerve. The AN was identified as it coursed anterior to the subscapularis, followed by its dissection as distally as

TABLE 1. Length of AN Exposed (%), Combining Approaches

Specimen	First Approach	6 O'Clock Position Visualized	Length of AN Exposed (%)	Second Approach	6 O'Clock Position Visualized	Additional Exposure (%)	Third Approach	6 O'Clock Position Visualized	Additional Exposure (%)	Total Exposure (%)
1	Medial to CJT	No	42	Lateral to CJT	Yes	38	Axillary	Yes	9	89
2	Lateral to CJT	Yes	46	Medial to CJT	No	18	Axillary	Yes	19	83
3	Axillary	Yes	50	Lateral to CJT	Yes	28	Medial to CJT	No	16	94
4	Axillary	Yes	53	Lateral to CJT	Yes	18	Medial to CJT	No	9	81

possible, avoiding injury to the circumflex vessels (Fig. 3). Its proximal course toward the lateral cord through this interval was dissected and measured as well.

Axillary approach

The arm was positioned in 90° of abduction and external rotation. The skin incision was performed as described by Bertelli et al,[8] in line with the anterior axillary line, then directed posteriorly to the apex of the axilla, and then again directed anteriorly to follow a line that continues the deltopectoral approach. The skin interval between the anterior axillary line and the deltopectoral approach is wide enough to allow safe exposure without risk of skin necrosis. If needed (ie, for lower brachial plexus exploration), both skin incisions can be connected with an oblique incision. Dissection of the subcutaneous tissue, identification of the latissimus dorsi, long head of triceps, and subscapularis muscles was performed. The AN was identified at the quadrangular space along with the posterior humeral circumflex artery. The anterior and posterior branches of the AN were identified and marked (Fig. 4).

The blind spot was defined by Maldonado et al[10] as a 1.6-cm segment of the AN just anterior to the 6 o'clock position of the glenohumeral joint. This point coincides with the origin of the long head of the triceps. Therefore, the dissected AN and its relationship with the origin of the long head of the triceps was documented.

After the AN was dissected by the first approach in the sequence, the exposed proximal and distal ends of the nerve were marked with a titanium clip for reference. The nerve exposed by the second and third approaches in the sequence were also marked with titanium clips to identify the total length of the nerve exposed using combined approaches.

Once the dissections were completed, the AN was excised with all its branches from its origin at the posterior cord (with part of the radial nerve for reference) to the neuromuscular junctions of the deltoid and teres minor. Digital photographs were taken, using a ruler as reference for later measurements. Length measurements were performed with imaging processing software Image J (National Institutes of Health, https://imagej.nih.gov). We defined the total length of the AN as the mean distance from the origin of the nerve at the posterior cord to the anterior and middle deltoid branches of the anterior division of the axillary nerve and the posterior deltoid and teres minor branches of the posterior division.

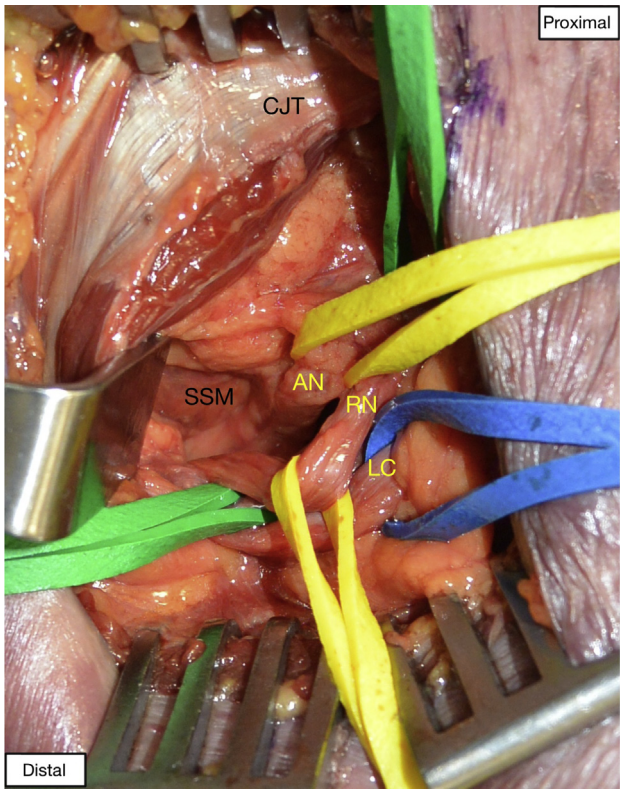

FIGURE 2: Right shoulder: deltopectoral approach medial to the CJT. RN, radial nerve; LC, lateral cord; SSM, subscapularis muscle.

RESULTS

Sequence A: medial to the CJT—lateral to the CJT—axillary

Using the deltopectoral approach with the interval medial to the CJT, we were able to identify the nerve proximally at its origin from the posterior cord, but were unable to continue laterally owing to the coracobrachialis and the short head of the biceps. However, when the interval lateral to the CJT was added, the AN could be followed beyond the coracobrachialis to the inferior border of the glenoid (the 6-o'clock position). At this point, the nerve could be adequately inspected and neurolyzed from potential scar tissue, but sufficient exposure for a nerve repair or graft would be difficult were it necessary to expose or manipulate the nerve distal to the 6-o'clock position.

When the axillary approach was added, the nerve could be traced distally identifying its anterior and posterior divisions, but not the neuromuscular junction (Fig. 5). The amount of exposure achieved by each sequential approach is shown in Table 1.

Sequence B: lateral to the CJT—medial to the CJT—axillary approaches

Using the interval lateral to the CJT, we were able to visualize and dissect the AN past the 6 o'clock point

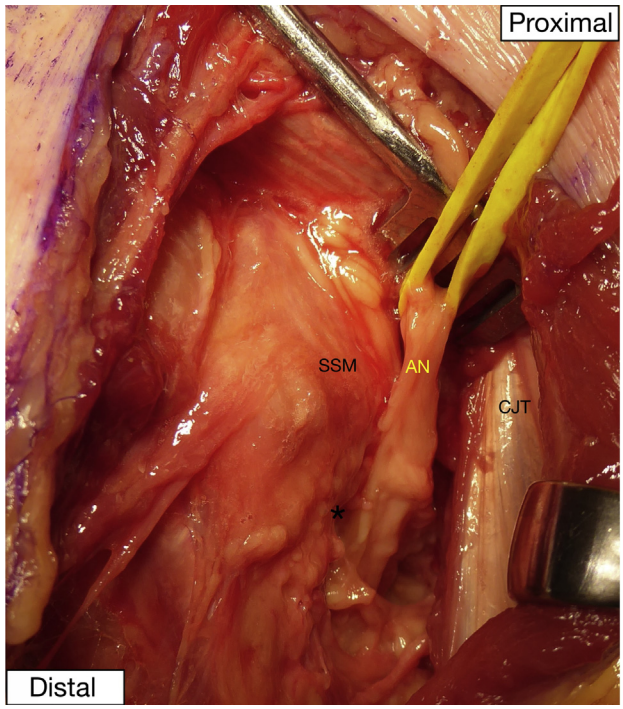

FIGURE 3: Right shoulder: deltopectoral approach lateral to the CJT. SSM, subscapularis muscle; *6-óclock position.

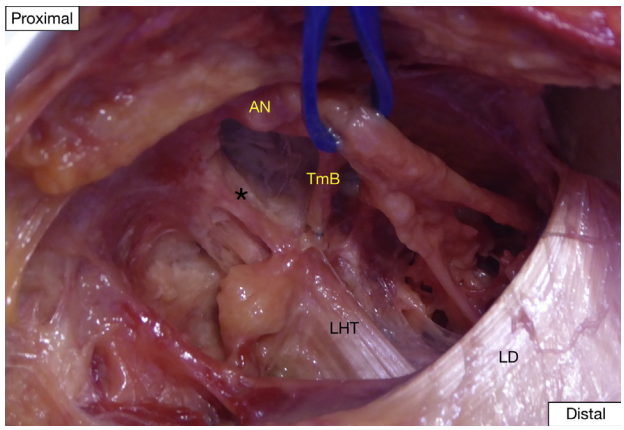

FIGURE 4: Left shoulder: axillary approach. LHT, long head of triceps; LD, latissimus dorsi; TmB, teres minor branch; *6-óclock position.

where the nerve split into anterior and posterior branches. However, the CJT impeded dissection of the nerve proximally and visualization of its origin from the posterior cord. Exploring the nerve medial to the CJT was required to enable visualization of the posterior cord origin. Adding the axillary approach increased the distal exposure, allowing better visualization of the anterior and posterior division as well as the terminal branches to the teres minor and posterior deltoid (Fig. 6 and Table 1).

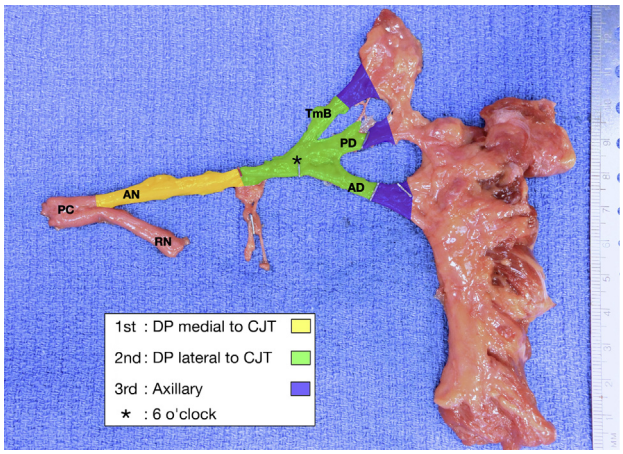

FIGURE 5: The AN excised. Colors reflect the additional exposed nerve in the sequence A-B-C. AD, anterior deltoid branch; DP, deltopectoral approach; PC, posterior cord; PD, posterior deltoid branch; RN, radial nerve; TmB, teres minor branch.

Sequence C: axillary approach—lateral to the CJT—medial to the CJT

From distal to proximal, the axillary approach allowed the exposure of the anterior and posterior divisions, its terminal branches to the teres minor and posterior deltoid (but not the nerve-muscle junction), and visualization of the 6-o'clock position of the glenoid. The exposure was limited proximally; 47% to 50% of the AN could not be visualized through this approach alone. By extending the incision proximally along the deltopectoral groove, both deltopectoral intervals could be utilized to visualize the entire nerve to the origin from the posterior cord (Fig. 7 and Table 1).

DISCUSSION

As previously described by Maldonado et al,[10] the deltopectoral approach medial to the CJT did not allow visualization of the AN near the inferior glenoid at the 5 o'clock position in right shoulders and the 7 o'clock position in left shoulders. However, when the window lateral to the CJT was opened in our study, we were able to effectively expose the blind spot at the 6 o'clock position. It is important to note that this was accomplished without detaching either the CJT from the coracoid process,[11] a portion of the latissimus dorsi or the anterior insertion of deltoid.[6]

The improved visualization of the AN by utilizing a lateral deltopectoral interval via the same incision would allow the surgeon to confirm the integrity of the nerve or to perform a neurolysis, all the way to the 6 o'clock position on the glenoid. We feel that the lateral CJT window is preferable to the use of a

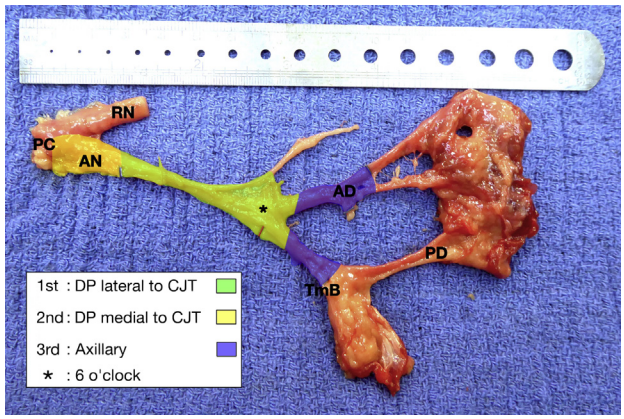

FIGURE 6: The AN excised. Colors reflect the additional exposed nerve in the sequence B-A-C. AD, Anterior deltoid branch; DP, deltopectoral approach; PC, posterior cord; PD, posterior deltoid branch; RN, radial nerve; TmB, teres minor branch.

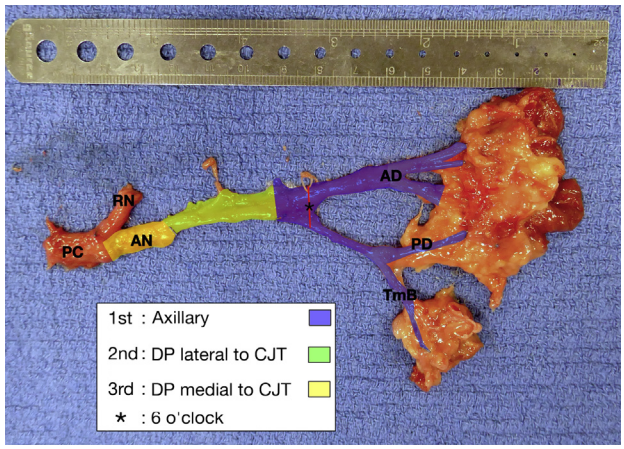

FIGURE 7: The AN excised. Colors reflect the additional exposed nerve in the sequence C-B-A. AD, anterior deltoid branch; DP, deltopectoral approach; PC, posterior cord; PD, posterior deltoid branch; RN, radial nerve; TmB, teres minor branch.

posterior incision because it does not require repositioning in a lateral or prone position.

Nerve repair or grafting/transfer at the 6 o'clock position would be difficult with the 2-window deltopectoral approach owing to the proximity of the axillary and circumflex vessels and the limited space for microsurgical instruments. In this case, the incision can easily be extended to enable an axillary approach. An articulated arm-holding device provides the necessary shoulder abduction and external rotation without repositioning the patient. This 3-window approach allows safe exploration of the entire AN to its bifurcation distal to the inferior glenoid. The current study supports use of a 3-window approach through 1 skin incision, deltopectoral

medial to the CJT, deltopectoral lateral to the CJT, and axillary.

Limitations of this study are those inherent to all cadaveric studies. The vascular structures were less prominent and there was the obvious lack of need for hemostasis. Owing to the limited number of dissected specimens, it was not possible to conduct a statistical analysis. It is possible that individual variations such as muscular mass or adipose tissue in obese patients could affect the amount of AN that can be exposed.

In summary, this study supports that injuries to the AN at the 6 o'clock position of the glenoid can be visualized, repaired, or reconstructed with a combination of deltopectoral and axillary approaches, using a single incision in the supine or beach chair position. The lateral deltopectoral approach is an important exposure that readily facilitates AN exposure to the inferior glenoid. With adequate preoperative planning and an arm-positioning device, all approaches could be done without repositioning the patient, muscular release, or a posterior incision.

REFERENCES

1. Carofino BC, Brogan DM, Kircher MF, et al. Iatrogenic nerve injuries during shoulder surgery. *J Bone Joint Surg Am*. 2013;95(18):1667–1674.
2. Bokor DJ, Raniga S, Graham PL. Axillary nerve position in humeral avulsions of the glenohumeral ligament. *Orthop J Sport Med*. 2018;6(12):232596711881104.
3. Eakin CL, Dvirnak P, Miller CM, Hawkins RJ. The relationship of the axillary nerve to arthroscopically placed capsulolabral sutures. An anatomic study. *Am J Sports Med*. 1998;26(4):505–509.
4. Yoo JC, Kim JH, Ahn JH, Lee SH. Arthroscopic perspective of the axillary nerve in relation to the glenoid and arm position: a cadaveric study. *Arthroscopy*. 2007;23(12):1271–1277.
5. Cuéllar A, Cuéllar R, Heredia JD, Cuéllar A, Ruiz-Ibán MA. Effect of patient positioning in axillary nerve safety during arthroscopic inferior glenohumeral ligament plication. *Knee Surg Sport Traumatol Arthrosc*. 2017;25(10):3279–3284.
6. Henry AK. The upper limb and neck. In: Henry AK, ed. *Extensil Exposure*. 2nd ed. Baltimore: Churchill Livingstone; 1973:39–44.
7. Crenshaw AH. Surgical techniques and approaches. In: Azar FM, Canale ST, Beaty JH, eds. *Campbell's Operative Orthopaedics*. 13th ed. Philadelphia: Elsevier Inc.; 2017:96–98.e3.
8. Bertelli JA, Kechele PR, Santos MA, Duarte H, Ghizoni MF. Axillary nerve repair by triceps motor branch transfer through an axillary access: anatomical basis and clinical results. *J Neurosurg*. 2007;107(2):370–377.
9. Leechavengvongs S, Witoonchart K, Uerpairojkit C, Thuvasethakul P. Nerve transfer to deltoid muscle using the nerve to the long head of the triceps, part II: a report of 7 cases. *J Hand Surg Am*. 2003;28(4):633–638.
10. Maldonado AA, Howe BM, Lawton R, Bishop AT, Shin AY, Spinner RJ. Anatomical study of the axillary nerve: description of a surgical blind zone. *Plast Reconstr Surg*. 2016;138(2):419–426.
11. Maldonado AA, Spinner RJ, Bishop AT, Shin AY, Elhassan BT. Effectiveness of the extended surgical approach to visualize the axillary nerve in the blind zone in an arthroscopic axillary nerve injury model. *J Plast Reconstr Aesthetic Surg*. 2016;69(12):1697–1703.